

## DIAGNOSTIC ULTRASOUND OF THE NON-PREGNANT FEMALE PELVIS – CLINICAL GUIDELINES (V1)

Version	Date	Purpose of Issue/Description of Change	Review Date
1	09/04/2018	Review and update of clinical guidelines	April 2020
<b>Status</b>			
<b>Publication Scheme</b>		HDFT INTRANET	
<b>FOI Classification</b>			
<b>Function/Activity</b>		CLINICAL GUIDELINES	
<b>Record Type</b>		CLINICAL GUIDELINES	
<b>Project Name</b>		DIAGNOSTIC ULTRASOUND OF THE NON-PREGNANT FEMALE PELVIS	
<b>Key Words</b>		DIAGNOSTIC ULTRASOUND OF THE NON-PREGNANT FEMALE PELVIS	
<b>Standard</b>			
<b>Author</b>		LOUISE WHITE – Principal Radiographer (Ultrasound)	<b>09/04/2018</b>
<b>Approval and/or Ratification Body</b>			

## 1. DIAGNOSTIC ULTRASOUND OF THE NON-PREGNANT FEMALE PELVIS – CLINICAL GUIDELINES (V1)

### 1.1. Scope

This policy guideline applies to all non-pregnant female patients referred for diagnostic gynaecological ultrasound to HDFT NHS TRUST

### 1.2. Guideline

The purpose of this guideline is to aid the ultrasound practitioner to assimilate, evaluate and implement the vast amount of evidence of opinion on best current ultrasound practice. To bridge the gap between academic research and everyday practice that is the key to clinical effectiveness and clinical governance.

Providing information specific to the ultrasound examination type this guideline aims to assist the practitioner to performing an appropriate examination dependant on referral criteria and clinical indications that will progress the patient management

### 1.3. Definitions

IUCD	Intra Uterine Contraceptive Device
LMP	Last Menstrual Period (documented from first day)
PMB	Post-Menopausal Bleeding
POD	Pouch of Douglas
Practitioner	Sonographer, Consultant Radiologist, Radiology Registrar
TA	Transabdominal
TV	Transvaginal

### 1.4. Authorised referrers and sources

A request for a pelvic ultrasound examination is made electronically via ICE. Handwritten paper request on a standard Ultrasound Request Form or formal letter currently remains an acceptable method of requesting.

Authorised referrers are all Medical Doctors, authorised Midwives and authorised Nurse Specialists/Practitioners.

### 1.5. Ultrasound Practitioner

An ultrasound practitioner is an individual who has obtained relevant and appropriate education and clinical experience. He/she will also have demonstrated competency to undertake diagnostic, screening or therapy procedures enabling effective management of the patient pathway. Ultrasound Practitioners are autonomous practitioners who perform with high levels of accountability and responsibility. They exercise critical judgement

and skills to ensure the efficient, effective and safe delivery of the ultrasound service, taking responsibility for the conduct, assessment and reporting of the ultrasound examination. The scope of practice is therefore broad and normal practice usually includes several clinical fields (each of which are wide ranging in scope). For the purpose of this guideline the clinical field of speciality is the non-pregnant female pelvis.

#### **1.6. Vetting and appointing examinations**

All requests are processed in accordance with Radiology standard operating procedures. This includes justification by an Ultrasound Practitioner (by agreement, specific examination designations do not require justification prior to appointing), and appointing with appropriate examination preparation and patient information by a clerical officer.

Examination of the non-pregnant female pelvis is categorised into pelvic ultrasound examination types by the Practitioner dependent on the clinical history and indication. Examination designations are listed in the Appendix 3.

#### **1.7. Practitioner Observations and Image Archiving**

- Reference any previous imaging reports and make comparison with any previous imaging on PACS where relevant and available.
- Observations to confirm normal anatomy or variants within the pelvic region.
- Maximum dimensions measured of any detected abnormalities. Colour flow Doppler +/- spectral characterisation of detected abnormalities may be performed if appropriate.
- Examination specific observations are listed for each examination type in the Appendices. Only those images which demonstrate the examination matching the clinical request need be acquired. These images are archived to PACS

#### **1.8. Decontamination of the Ultrasound Probe**

The ultrasound probes should be cleaned on completion of the examination in accordance with departmental guidance (Appendix 3)

#### **1.9. Reporting**

Reporting is carried out in accordance with Radiology Standard Operating Procedures / Radiology Requesting and Reporting Policy.

Standardised report phrases are available for use within the Reporting Package of the Radiology CRIS system. The use of these phrases is not mandatory and the phrases are not exhaustive or complete in describing all ultrasound appearances demonstrated on examination of the female pelvis. Reporting phrases are listed in Appendix 14

Reporting in accordance with Radiology Reporting Protocol

## **2. CONSULTATION, APPROVAL AND RATIFICATION PROCESS**

The Consultation process is summarised and approved by those listed in Appendix 1

This Guideline is ratified by Principal Radiographer in Ultrasound

## **3. DOCUMENT CONTROL**

This Guideline Document will be published to the Trust's Intranet.

The author, in conjunction with document library administrator, will be responsible for ensuring archiving of replaced electronic versions within the document library, as evidence of previous policy.

Only essential copies of this policy documents will be printed to reduce the risk of out of date policies being in circulation.

## **4. DISSEMINATION AND IMPLEMENTATION**

### **4.1.1. Dissemination**

The publication of this guideline on the Harrogate and District NHS Foundation Trust Intranet will be notified at Radiology MDT, Radiology Senior Staff Meeting, Ultrasound Staff Meeting, and Joint Radiology & Obstetric Meeting and be emailed to individual Ultrasound Practitioners in Radiology. Revisions and amendments will be notified as above.

### **4.1.2. Implementation**

Any appropriate training and support which is required for staff will be provided.

## **5. MONITORING COMPLIANCE AND EFFECTIVENESS**

### **5.1. Standards/ Key Performance Indicators**

See Appendix 2

### **5.2. Process for monitoring compliance**

Monitoring of compliance to this Guideline will be through an internal and external audit process and through the incident reporting system

## **6. REFERENCE AND ASSOCIATED DOCUMENTS**

Radiology Requesting and Reporting Policy (Intranet)

SOP 007 Vetting (Radiology Public Files)

Communication of Examination Results to Patients (Departmental Policy)

RMI Index

## **7. APPENDICES**

- Appendix 1: Consultation Summary
- Appendix 2: Monitoring, audit and feedback summary
- Appendix 3: Gynaecological Ultrasound – List of examination designations
- Appendix 4: Flow Chart Decontamination of the Ultrasound Probe
- Appendix 5: Transabdominal Routine
- Appendix 6: Transvaginal Routine
- Appendix 7: Ovarian Cyst - Premenopausal
- Appendix 8: Ovarian Cyst - Postmenopausal
- Appendix 9: PMB clinic
- Appendix 10: Myometrial Thickness
- Appendix 11: PCOS
- Appendix 12: Pelvic - Persistent Bloating
- Appendix 13: HyCoSy
- Appendix 14: Standard Reporting Phrases

## Appendix 1: Consultation Summary

<p><b>Those listed opposite have been consulted and any comments/actions incorporated as appropriate.</b></p> <p>The author must ensure that relevant individuals/groups have been involved in consultation as required prior to this document being submitted for approval.</p>	<p><b>List Groups and/or Individuals Consulted</b></p>
	Allison Amin – Consultant in Obstetrics and Gynaecology
	Dr Ashley Uttley – Consultant Radiologist
	Dr H Moss – Consultant Radiologist
	Dr Adam Culverwell – Consultant Radiologist & Radiology Clinical Lead
	Louise White – Principal Radiographer Ultrasound (author)

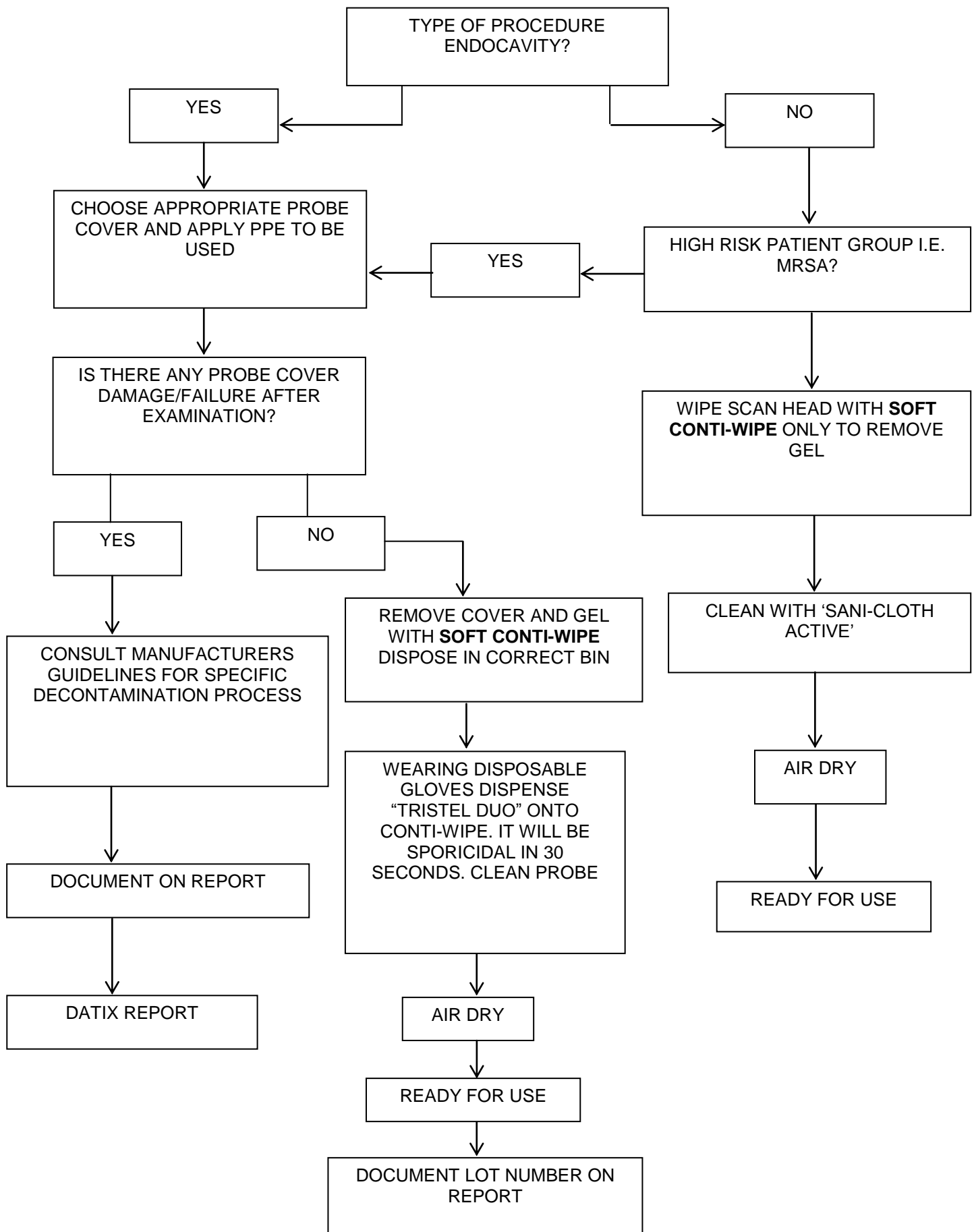
## Appendix 2: Monitoring, Audit and Feedback Summary

KPIs	Audit / Monitoring required	Audit / Monitoring performed by	Audit / Monitoring frequency	Audit / Monitoring reported to	Concerns with results escalated to
That Ultrasound request has been made by appropriate health professional	YES	Designated Sonographer in gynaecological Ultrasound	Annually	Dr A Uttley	Clinical Lead in Radiology
That indications for ultrasound are appropriate	YES	Designated Sonographer in gynaecological Ultrasound	Annually	Dr A Uttley	Clinical Lead in Radiology
That the examination is reported in line with these guidelines	YES	Designated Sonographer in gynaecological Ultrasound	Annually	Dr A Uttley	Clinical Lead in Radiology

## Appendix 3: Gynaecological Ultrasound – List of examination designations

Transabdominal – Routine  
 Transvaginal – Routine  
 Ovarian Cyst – Premenopausal  
 Ovarian Cyst – Postmenopausal  
 PMB  
 Myometrial Thickness  
 Polycystic Ovaries  
 Pelvic (persistent bloating)  
 HyCoSy

### Appendix 4: Flow Chart Decontamination of the Ultrasound Probe





## Appendix 5: Pelvic Transabdominal Routine

EXAM TYPE	<b>8. PEVIC – TRANSABDOMINAL ROUTINE</b>
AUTHORISED REFERERS & SOURCES	ALL MEDICAL DOCTORS AUTHORISED MIDWIVES/EPAU (Pregnancy Remains) AUTHORISED NURSE PRACTITIONERS (PMB)
REFERAL CRITERIA & CLINICAL INDICATIONS	<ul style="list-style-type: none"> <li>• Mass</li> <li>• Enlarged uterus</li> <li>• Irregular/abnormal menses</li> <li>• Post-menopausal bleeding – urgent appointment within 2 weeks</li> <li>• IUCD localisation</li> <li>• Pelvic Pain</li> <li>• 1# or 2# infertility</li> <li>• Appendicitis</li> <li>• FH Ca ovary – following geneticist review</li> <li>• <b><i>Persistent bloating, early satiety, pelvic or abdominal pain, increased urinary urgency and/or frequency – See dedicated guideline</i></b></li> <li>• <b><i>PMB Clinic – TV technique only - See dedicated guideline</i></b></li> <li>• <b><i>F/U cysts – See dedicated guideline</i></b></li> <li>• <b><i>Pregnancy Remains – see dedicated guideline (in Obstetric Guideline)</i></b></li> <li>• <b><i>PCOS – See dedicated guideline</i></b></li> <li>• <b><i>Myometrial thickness – see dedicated guideline</i></b></li> </ul>
OBSERVATIONS	<ul style="list-style-type: none"> <li>• Comparison with previous reports and/or imaging where relevant and available</li> <li>• Confirm normal anatomy/variants of the uterus, cervix, Pouch of Douglas, ovaries and adnexa, including pre or post-menopausal related appearances of organs</li> <li>• Endometrial thickness and uniformity (measured in longitudinal section as the double wall thickness including both anterior and posterior endometrial walls)</li> <li>• Maximum dimensions of any detected abnormalities</li> <li>• Colour flow +/- spectral Doppler characteristics of detected abnormalities if appropriate (not in 1<sup>st</sup> trimester viable pregnancy)</li> <li>• Kidneys and urinary bladder when indicated</li> <li>• Non-fasted upper abdomen when malignancy/ascites/additional alternative pathology suspected</li> </ul>
REPORTING GUIDELINES	CRIS reporting system - electronic issue of verified reports – Highlight any urgent findings Non-routine or urgent abnormal findings send unverified provisional report to appropriate Radiologist worklist.
COMMENTS	<ul style="list-style-type: none"> <li>• 20 minute appointment time</li> <li>• Use of TV to obtain additional information when required</li> <li>• If proceeding to TV when TA exam inadequate (e.g. BMI, incomplete or unsuccessful bladder filling please take a representative TA image)</li> </ul>

	<ul style="list-style-type: none"> <li>• <b><i>IUCD – if not demonstrated on ultrasound progress to abdominal x-ray (IRMER rules to apply)</i></b></li> </ul>
REFERENCES SOURCES	College of Radiographers Royal College of Radiologists Royal College of Obstetricians and Gynaecologists
AUTHOR & DATE	Alison Gillespie December 2004 Reviewed and amended A. Gillespie April 2008 Reviewed LW Nov 2011 Reviewed LW July 2013 Reviewed LW Sept 2015 Reviewed and amended L. White February 2018

## Appendix 6: Transvaginal Routine

EXAM TYPE	<b>9. PEVIC – TRANSVAGINAL ROUTINE</b>
AUTHORISED REFERERS & SOURCES	ALL MEDICAL DOCTORS AUTHORISED MIDWIVES/EPAU (Pregnancy Remains) AUTHORISED NURSE PRACTITIONERS (PMB)
REFERAL CRITERIA & CLINICAL INDICATIONS	<ul style="list-style-type: none"> <li>• <b><i>As transabdominal ultrasound</i></b></li> </ul>
OBSERVATIONS	<ul style="list-style-type: none"> <li>• Comparison with previous reports and/or imaging where relevant and available</li> <li>• Confirm normal anatomy/variants of the uterus, cervix, POD and ovaries and adnexae, including any pre or post-menopausal related appearances of organs.</li> <li>• Endometrial thickness and uniformity (measure in longitudinal section as the double wall thickness including both anterior and posterior endometrial walls)</li> <li>• Maximum dimensions of any detected abnormalities</li> <li>• Colour flow +/- spectral Doppler characteristics of detected abnormalities if appropriate</li> <li>• Kidneys and urinary bladder when indicated</li> <li>• Non-fasted upper abdomen when malignancy/ascites/additional or alternative pathology suspected</li> </ul>
REPORTING GUIDELINES	CRIS reporting system - electronic issue of verified reports – Highlight any urgent findings Non-routine or urgent abnormal findings send unverified provisional report to appropriate Radiologist worklist.
COMMENTS	<ul style="list-style-type: none"> <li>• 20 minute examination time</li> <li>• Latex free consumables used as standard</li> <li>• Probe cover to be changed in any event of reinsertion</li> <li>• Informed verbal consent a necessity</li> <li>• Maximum privacy afforded</li> <li>• Chaperone to female operator offered and available on request</li> <li>• Chaperone to male operator necessity</li> <li>• Contraindications: Virgo intacta, vaginismus, radiation fibrosis, anal fissures, vaginal atrophy</li> <li>• IUCD – if not demonstrated on ultrasound progress to abdominal x-ray (IRMER rules to apply)</li> </ul>
REFERENCES SOURCES	College of Radiographers Royal College of Radiologists Royal College of Obstetricians and Gynaecologists Nice Clinical Guidelines 122
AUTHOR & DATE	Alison Gillespie December 2004 Reviewed and amended A.Gillespie April 2008 Reviewed + amended LW Nov 2011 Reviewed and amended LW July 2013 Reviewed and amended LW Sept 2015 Reviewed LW March 2018

## Appendix 7: Ovarian Cyst – Pre-menopausal

EXAM TYPE	<b>PEVIC – OVARIAN CYST – Pre-menopausal</b>
AUTHORISED REFERERS & SOURCES	ALL MEDICAL DOCTORS
REFERAL CRITERIA & CLINICAL INDICATIONS	<i>As Pelvic ultrasound</i>
OBSERVATIONS	In addition to those listed in transabdominal/transvaginal guideline specific observations should include :- <ul style="list-style-type: none"> <li>• Multiplicity of cysts</li> <li>• Thickness / regularity of cyst wall</li> <li>• Multilocular / unilocular</li> <li>• Presence/number/thickness of septae</li> <li>• Characterisation of any internal solid components, echoes or papillary growths – Colour Doppler may be useful but not essential*</li> </ul>
REPORTING GUIDELINES	<ol style="list-style-type: none"> <li>1. <b>Non-symptomatic follicular and corpus luteal cyst of less than 5cm should not be reported</b></li> <li>2. <b>Symptomatic simple cyst up to 5cm should be reported with comment – “A clinical follow up is required but as per guidelines no routine repeat ultrasound is necessary”.</b></li> <li>3. <b>Non-symptomatic simple cyst 5cm – 7cm which is:-</b> <ul style="list-style-type: none"> <li>• Simple and thin walled</li> <li>• Thin septae</li> <li>• May contains homogeneous echoes</li> <li>• <b>Report “ A gynaecological referral/follow up is recommended with a routine rescan in 1 year unless advised otherwise by Senior Clinician”</b></li> <li>• If still present at follow up – Radiologist report)</li> </ul> </li> <li>4. <b>Symptomatic simple cyst 5 -7 cm – “A gynaecological follow up is recommended , any ultrasound follow up should be advised by Senior Clinician</b></li> <li>5. <b>Cysts greater than 7cm, multiples, or any cyst which is complex or any suspicious findings – Radiologist for report (Gynaecological follow up and CA125 will be recommended and Risk of Malignancy Index RMI calculated )</b></li> </ol>
REPORTING PHRASES	CRIS reporting system - electronic issue of verified reports – Highlight report for any urgent findings Document non-consent to TV scan if applicable Non-routine or urgent abnormal findings send unverified provisional report to appropriate Radiologist worklist for reporting

COMMENTS	<ul style="list-style-type: none"> <li>• 20 minute appointment time</li> <li>• TV technique is recommended and has increased sensitivity in evaluating ovarian masses*</li> <li>• A combination of TA and TV may be appropriate for the assessment of larger masses and extra-ovarian disease*</li> <li>• <b>Simple cysts up to 10cm have little chance of malignancy – Yorkshire Cancer Network Group August 2011</b></li> </ul>
REFERENCES SOURCES	Local Practice - ultrasound Management Team Yorkshire Cancer Network Group *RGOC Green-top guideline 62 - Nov 2011
AUTHOR & DATE	Louise White May 2005 Reviewed and amended M Faulkner/L White October 2008 Reviewed and amended Nov 2011 LW Reviewed and amended July 2013 LW/DAS Reviewed and amended Sept 2015 LW/Allison Amin Reviewed and amended A. Amin/ A. Uttley Feb2018

## Appendix 8: Ovarian Cyst Post-menopausal

EXAM TYPE	<b>PEVIC – OVARIAN CYST – Post menopausal</b>
AUTHORISED REFERERS & SOURCES	ALL MEDICAL DOCTORS
REFERAL CRITERIA & CLINICAL INDICATIONS	<i>As Pelvic ultrasound</i>
OBSERVATIONS	In addition to those listed in transabdominal/transvaginal guideline specific observations should include :- <ul style="list-style-type: none"> <li>• Multiplicity of cysts</li> <li>• Thickness / regularity of cyst wall</li> <li>• Multilocular / unilocular</li> <li>• Presence/number/thickness of septae</li> <li>• Characterisation of any internal solid components, echoes or papillary growths</li> <li>• Presence of bilateral lesions</li> <li>• Evidence of ascites</li> <li>• Evidence of metastases</li> </ul>
REPORTING GUIDELINES	CRIS reporting system – electronic issue of verified reports – use Highlighted report for any urgent findings <ol style="list-style-type: none"> <li>1. At initial finding of any <b>simple unilateral cyst between 2-5cms</b> recommend a rescan in 4-6 months</li> <li>2. Subsequent scans – if simple cyst still present and unchanged recommend follow up scan after a 4 – 6 month interval. However if cyst has decreased in size or has resolved, discharge with no further scan.</li> <li>3. At scan <b>1 year from initial diagnosis</b>, if still present unchanged or reduced in size – no further scan is recommended (as per RCOG guidelines) Management will be decided by Clinician</li> <li>4. <b>Cysts greater than 5cm, or any size cyst which is complex, bilateral or any suspicious findings</b> – Radiologist for report (RMI referenced ) - will be referred to Gynaecologist</li> </ol>
REPORTING CODES	CRIS Reporting codes available
COMMENTS	<ul style="list-style-type: none"> <li>• 20 minute appointment time</li> <li>• Use of TV to obtain additional information when required</li> <li>• It is recommended that a 'risk of malignancy index' RMI should be calculated to select appropriate cancer treatment centre</li> <li>• It is recommended that ovarian cysts in postmenopausal women should be assessed using CA125 and transvaginal grey scale sonography. <b>There is no routine role yet for Doppler, MRI, CT or PET.</b></li> </ul>

REFERENCES SOURCES	<b>Royal College of Obstetricians and Gynaecologists – Guideline 34; October 2003 (Reviewed 2010)</b> <b>NICE Guideline 122</b> Local Practice - ultrasound Management Team
AUTHOR & DATE	Louise White May 2005 Reviewed and amended M Faulkner/L White October 2008 Reviewed and amended Nov 2011 LW Reviewed and amended June 2013 LW/DAS Reviewed and amended Version II Sept 2015 LW Reviewed and amended by A. Amin & A Uttley Feb/March 2018

## Appendix 9: PMB Clinic

EXAM TYPE	<b>PEVIC – PMB Clinic</b>
AUTHORISED REFERERS & SOURCES	ALL MEDICAL DOCTORS AUTHORISED NURSE SPECIALIST/PRACTITIONER (PMB)
REFERAL CRITERIA & CLINICAL INDICATIONS	<ul style="list-style-type: none"> <li>• Prior to planned hysteroscopy +/- Biopsy</li> <li>• Patients referred to Gynaecology with PMB are pre-booked by the Women’s Unit to attend PMB one stop clinic (electronic vetting /justification not required)</li> <li>• Also from Gynae clinic or emergency admission from ward</li> <li>•</li> </ul>
OBSERVATIONS	As observations for Pelvic – transvaginal with high priority for:- <ul style="list-style-type: none"> <li>• Endometrial thickness and uniformity (measured in longitudinal section as the double wall thickness including both anterior and posterior endometrial walls)</li> </ul>
REPORTING GUIDELINES	CRIS reporting system - electronic issue of verified reports – Highlight any urgent findings Immediate reporting required for ‘One-Stop’ PMB Clinic <b>Upper limit of normal for endometrial thickness <math>\leq</math> 4mm</b>  Urgent complicated abnormal findings – Discuss with available Radiologist and organise immediate report.
REPORTING CODES	Use of CRIS Reporting Code for routine normal report or free text if required
COMMENTS	<ul style="list-style-type: none"> <li>• Transvaginal examination</li> <li>• Compulsory informed verbal consent Maximum privacy afforded – Record non consent on report</li> <li>• Chaperone to female operator offered and available on request</li> <li>• Chaperone to male operator necessity</li> <li>• Latex free consumables used as standard</li> <li>• Probe cover to be changed in any event of reinsertion</li> <li>• Contraindications: Virgo intacta, vaginismus, radiation fibrosis, anal fissures, vaginal atrophy</li> </ul>
REFERENCES SOURCES	Local practice
AUTHOR & DATE	L. White Nov 2011 Reviewed August 2013 LW Reviewed and amended LW Sept 2015 Review and amended LW/AA March 2018



## Appendix 10: Myometrial Thickness

<b>EXAM TYPE</b>	<b>PELVIC – MYOMETRIAL THICKNESS</b>
AUTHORISED REFERERS & SOURCES	CONSULTANT
REFERAL CRITERIA & CLINICAL INDICATIONS	<ul style="list-style-type: none"> <li>• Prior to endometrial ablation with Novasure System for identification of contra-indications, such as endometrial carcinoma, fibroids, thin myometrium etc.</li> <li>• Previous Caesarean section</li> </ul>
OBSERVATIONS	<ul style="list-style-type: none"> <li>• In addition to observations listed in transabdominal and transvaginal guidelines the thickness of the myometrium should be measured at its thinnest point whilst scanning the uterus in longitudinal section. In cases of previous caesarean section it is usually at this site</li> </ul>
REPORTING GUIDELINES	CRIS reporting system Highlighted report for any urgent findings
COMMENTS	<ul style="list-style-type: none"> <li>• 20 minute appointment time</li> <li>• Transvaginal approach preferable to obtain accurate data/measurements</li> <li>• Please refer to Transabdominal and Transvaginal guidelines</li> </ul>
REFERENCES SOURCES	Local practice Ultrasound Management Meeting Sept 2005 National Institute for Clinical Excellence - Interventional Procedure Guidance 7 (2003)
AUTHOR & DATE	Alison Gillespie December 2004 Reviewed and amended A.Gillespie April 2008 Reviewed LW Nov 2011 Review and update LW September 2015 Reviewed LW/AA March 2018

## Appendix 11: PCOS

<b>EXAM TYPE</b>	<b>PELVIC – POLYCYSTIC OVARIES</b>
AUTHORISED REFERERS & SOURCES	CONSULTANT GP
REFERAL CRITERIA & CLINICAL INDICATIONS	Amenorrhoea or oligomenorrhoea Hirsutism Associated obesity
OBSERVATIONS	Additional to observations listed in routine transabdominal/transvaginal ultrasound:- <ul style="list-style-type: none"> <li>• Measurement of ovarian volume (greater than 10mls to suggest PCOS)</li> <li>• Note of number of follicles between 2-9mm (more than 12 to suggest PCOS)</li> <li>• <b>Both Kidneys to include supra-renal area</b></li> </ul>
REPORTING GUIDELINES	CRIS reporting system – electronic issue of verified reports - Highlight any urgent findings  Appearances suggestive of PCOS – Sonographer Reporting phrases Non-routine, complex or abnormal findings – send unverified provisional report to appropriate Radiologist worklist
COMMENTS	<ul style="list-style-type: none"> <li>• 20 minute examination time</li> <li>• Use of TV to obtain additional information when required</li> <li>• Latex free consumables as standard</li> <li>• Compulsory informed verbal consent</li> <li>• Maximum privacy afforded</li> <li>• Chaperone to female operator offered and available on request</li> <li>• Chaperone to male operator necessity</li> <li>• Probe cover to be changed in any event of reinsertion</li> <li>• Contraindications: Virgo intacta, vaginismus, radiation fibrosis, anal fissures, vaginal atrophy</li> </ul>
REFERENCES SOURCES	Ultrasound assessment of the polycystic ovary: international consensus definitions Adam H.Balen <sup>1,5</sup> , Joop S.E.Laven <sup>2</sup> , Seang-Lin Tan <sup>3</sup> and Didier Dewailly <sup>4</sup> <a href="http://humupd.oxfordjournals.org/content/9/6/505.full.pdf">humupd.oxfordjournals.org/content/9/6/505.full.pdf</a>
AUTHOR & DATE	Louise White May 2005 Reviewed and amended M Faulkner/L White October 2008 Reviewed Nov 2011 LW Reviewed/Updated L White July 2013 Review and amended LW Sept 2015 Reviewed LW March 2018

## Appendix 12: Pelvic – Persistent Bloating

<b>EXAM TYPE</b>	<b>PELVIC</b> <b>Suspected Ovarian Cancer in women with persistent bloating and/or associated symptoms.</b>
<b>AUTHORISED REFERERS &amp; SOURCES</b>	ALL MEDICAL DOCTORS
<b>REFERAL CRITERIA &amp; CLINICAL INDICATIONS</b>	<ul style="list-style-type: none"> <li>• Suspected ovarian cancer with reported symptoms of persistent bloating, early satiety, pelvic or abdominal pain, increased urinary urgency and/or frequency</li> <li>• Suspected ovarian cancer in women over 50 with reported symptoms of IBS within the last 12 months</li> <li>• Suspected ovarian cancer alongside other symptoms e.g. unexplained weight loss, fatigue, changes in bowel habit</li> </ul>
<b>OBSERVATIONS</b>	<ul style="list-style-type: none"> <li>• Comparison with previous reports/imaging where relevant and available</li> <li>• Confirm normal anatomy/variants of the uterus, cervix, POD, ovaries and adnexae, including pre and post-menopausal related appearances of organs</li> <li>• Endometrial thickness and uniformity (measured in longitudinal section as the double wall thickness including both anterior and posterior endometrial walls)</li> <li>• Maximum dimensions of any detected abnormalities</li> <li>• Colour flow +/- spectral characteristics of detected abnormalities if appropriate</li> <li>• Kidneys and urinary bladder when indicated</li> <li>• Non fasted upper abdomen when malignancy/ascites or alternative pathology suspected</li> </ul>
<b>REPORTING GUIDELINES</b>	CRIS reporting system – electronic issue of verified reports - Highlighted report for any urgent findings Non-routine or urgent abnormal findings – send unverified report to appropriate Radiologist worklist
<b>COMMENTS</b>	<ul style="list-style-type: none"> <li>• 20 minute appointment time</li> <li>• Initial examination protocolled as Pelvic Ultrasound with appropriate full bladder preparation</li> <li>• Use of TV to obtain additional information when required</li> <li>• If proceeding to TV due to inadequacy of TA exam (e.g. BMI, incomplete or unsuccessful bladder filling please take a representative TA image to demonstrate absence of any significant pelvic mass)</li> <li>• Proceed to upper abdominal survey (non-fasted) when malignancy/ascites suspected</li> </ul>
<b>REFERENCES SOURCES</b>	College of Radiographers Royal College of Radiologists RCOG Greentop guidelines 34 & 62 NICE Clinical Guideline 122
<b>AUTHOR &amp; DATE</b>	Louise White July 2013 Reviewed and amended LW Sept 2015 Reviewed LW March 2018

## Appendix 13: HyCoSy

<b>EXAM TYPE</b>	<b>HyCoSy</b>
AUTHORISED REFERERS & SOURCES	Consultant only – from gynaecology outpatients
REFERAL CRITERIA & CLINICAL INDICATIONS	<p>12 months primary or secondary infertility</p> <p>Examination booked via office after patient stops bleeding up to day 14 of cycle.</p> <p>Variations to be discussed with consultant.</p> <p>Pregnancy test for query amenorrhoea</p> <p>Written information given by referrer at time of examination.</p>
OBSERVATIONS	<p>Follow protocol for routine pelvic transvaginal scan including volumetric measurement of ovaries, pathology and relation of fibroids to the endometrial cavity.</p> <p>Image the position of catheter in situ.</p> <p>During procedure: 1-2mls of contrast injected into cavity. Further contrast as required. Both tubes imaged from cornua to ovary and spill demonstrated. Tubes observed for minimum of 5minutes to exclude spasm.</p> <p>Cine loops recorded</p>
REPORTING GUIDELINES	<p>Authorised sonographer reporting.</p> <p>Standard text plus free text where appropriate.</p> <p>Record names of operator and assistant/nurse present.</p> <p>Uncertain findings can be discussed with radiologist before report issued.</p>
REPORT PHRASES	CRIS generated. Use of standard report phrases (HyCoSy) or free text.
COMMENTS	<p>Patient must be informed of procedural risk to an early pregnancy. Verbal explanation and consent must be obtained.</p> <p>A record of LMP, current smear test, possible infections and pre examination painkillers must be made. Information recorded in the day book.</p> <p>Contrast batch number recorded in daybook and persons present.</p> <p>Patient should be constantly observed for signs of cervical shock.</p> <p>Examination always carried out with a second member of staff. A medical practitioner must be available to attend at immediate notice when contacted.</p> <p>45 minute appointment.</p> <p>If a patient has cervical stenosis, consultant is alerted before procedure.</p> <p>Patient must be given after care advice.</p>

REFERENCES	Hull IVF guidelines for HyCoSy Royal College of Radiologists 1998 Intimate Examinations UKAS guidelines on HyCoSy examinations HDH Gynaecological scan (TV) protocol 2015
AUTHOR & DATE	Collette Coppack Dec 2011 Review and amended by A.Gillespie Oct 2015 Reviewed by P.Kirkpatrick & A. Gillespie March 2018

## Appendix 14: Standard Reporting Phrases

<p>UGYN1 Normal gynae</p>	<p>LMP: Normal sized/slightly/bulky anteverted/retroverted uterus. The endometrium appears uniform and measures [01] mm. This is within normal limits and consistent with stage of menstrual cycle. (The upper limit of normal 14 mm pre-menopausal, 4 mm post-menopausal). No abnormality detected in either ovary. No adnexal masses or free fluid seen.</p>
<p>UGYN2 Early fibroid change</p>	<p>LMP: Normal sized/slightly/bulky anteverted/retroverted uterus. The uterus has a generalised heterogeneous echo texture in keeping with early leiomyomatous change or adenomyosis: but no focal fibroids detected The endometrium appears uniform and measures [01] mm. This is within normal limits and consistent with stage of menstrual cycle. (The upper limit of normal 14 mm pre-menopausal, 4 mm post-menopausal). No abnormality detected in either ovary. No adnexal masses or free fluid seen.</p>
<p>UGYN3 Fibroid</p>	<p>LMP: Bulky anteverted/retroverted uterus. There is a [01] mm intramural/subserosal/submucosal/pedunculated fibroid seen in the anterior/posterior/left/right/upper/lower uterus. The endometrium appears uniform and measures [02]mm. (Upper limit of normal = 14 mm pre-menopausal, 4 mm post-menopausal). No abnormality detected in either ovary. No adnexal masses or free fluid seen.</p>
<p>UGYN4 Multi-fibroid</p>	<p>LMP: Bulky anteverted/retroverted uterus. There are several fibroids seen. The largest is a [01]mm intramural/subserosal/submucosal fibroid seen in the anterior/posterior/left/right/upper/lower uterus. The endometrium measures [02]mm. (Upper limit of normal = 14 mm pre-menopausal, 4 mm post-menopausal). No abnormality detected in either ovary. No adnexal masses or free fluid seen.</p>
<p>UGYN5 Symptomatic simple cyst up to 50mm Premenopausal</p>	<p>LMP: Normal sized/slightly/bulky anteverted/retroverted uterus. The endometrium appears uniform and measures [01]mm. This is within normal limits and consistent with stage of menstrual cycle. (The upper limit of normal 14 mm pre-menopausal, 4 mm post-menopausal). The right/left ovary contains a [02]mm symptomatic simple cyst, which requires a clinical follow up, but as per guidelines, no repeat ultrasound is necessary. The right/left ovary appears normal. No adnexal masses or free fluid seen.</p>
<p>UGYN6 Asymptomatic 50-70mm simple cyst Premenopausal</p>	<p>Normal sized/slightly/bulky anteverted/retroverted uterus. The endometrium appears uniform and measures [01]mm. This is within normal limits and consistent with stage of menstrual cycle. (The upper limit of normal 14 mm pre-menopausal, 4 mm post-menopausal).</p>

	<p>The right/left ovary contains a [02]mm asymptomatic simple cyst.  The right/left ovary appears normal.  No adnexal masses or free fluid seen.  A gynaecological referral/follow- up is recommended with a routine rescan in 1 year unless otherwise advised by a Senior Clinician</p>
<p>UGYN7  Symptomatic 50-70mm simple cyst  Premenopausal</p>	<p>LMP:  Normal sized/slightly/bulky anteverted/retroverted uterus.  The endometrium appears uniform and measures [01]mm. This is within normal limits and consistent with stage of menstrual cycle. (The upper limit of normal 14 mm pre-menopausal, 4 mm post-menopausal).  The right/left ovary contains a [02]mm symptomatic simple cyst.  The right/left ovary appears normal.  No adnexal masses or free fluid seen.  A gynaecological referral/follow up is recommended, any ultrasound follow up should be advised by a Senior Clinician.</p>
<p>UGYN8  20-50mm simple cyst  Postmenopausal</p>	<p>Normal sized/slightly/bulky anteverted/retroverted post-menopausal uterus.  The endometrium appears uniform and measures [01]mm. (The upper limit of normal is 4mm post-menopausal).  The right/left ovary contains a [02]mm simple cyst. In accordance with postmenopausal patient local guidelines (simple cysts between 20mm-50mm), a rescan is recommended in 4 to 6 months.  The right/left ovary appears normal.  No adnexal masses or free fluid seen.</p>
<p>UGYN9  IUCD</p>	<p>LMP:  Normal sized/slightly/bulky anteverted/retroverted uterus.  The IUCD is identified within the endometrial cavity in a satisfactory position. The IUCD makes the endometrium technically difficult to assess but appears normal.  No abnormality detected in either ovary.  No adnexal masses or free fluid seen.</p>
<p>UGYN10  PCOS</p>	<p>LMP:  Normal sized/slightly/bulky anteverted/retroverted uterus.  The endometrium appears uniform and measures [01]mm. (The upper limit of normal 14 mm pre-menopausal, 4 mm post-menopausal).  The ovaries are enlarged, and contain multiple follicles measuring between 2 mm and 9 mm. These appearances are in keeping with, but not diagnostic of PCOS.  Right ovarian volume =  Left ovarian volume =  No adnexal masses or free fluid seen.</p>
<p>UGYN11  PMB Pathway</p>	<p>Patient referred via PMB clinic.  Routinely, only a transvaginal examination is performed.  Normal sized/slightly/bulky anteverted/retroverted post-menopausal uterus.  The endometrium appears uniform and measures [01]mm. (The upper limit of normal is 4mm post-menopausal).  Both ovaries of normal size and appearance.  No adnexal masses or free fluid seen.  TV examination performed with patient's verbal consent. Latex free consumables used as standard.  The transvaginal probe is cleaned in accordance with departmental guidelines using the Tristel Duo System. Lot number:</p>

<p>UGYN12 Follow up Postmen simple cyst</p>	<p>Normal sized/slightly/bulky anteverted/retroverted postmenopausal uterus. The endometrium appears uniform and measures ?mm (The upper limit of normal is 4mm post-menopausal) The previously noted right/left sided simple cyst remains unchanged and a further scan is recommended in 4 - 6 months The previously noted right/left sided simple cyst has reduced in size and now measures mm, no further follow up scan is required. The previously noted right/left sided simple cyst remains unchanged one year from initial diagnosis. No further scan is recommended and management will be decided by Senior Clinician The right/left ovary appears normal No adnexal masses or free fluid seen</p>
<p>HyCoSy</p>	<p>TV scan performed with patient's verbal consent. Latex free probe cover used as standard and cleaned according to departmental protocol using Tristel Duo System Lot number: Normal sized anteverted/retroverted uterus. The endometrium was uniform and measured mm. Normal appearances of both ovaries. Right ovarian volume = cc Left ovarian volume = cc The left/right ovary had a dominant follicle of mm. X mls of contrast media used (sonovue diluted 1:2 saline) Scan and Report by</p>
<p>UCONS</p>	<p>TV scan performed with patient's verbal consent. Latex free probe cover used as standard.  The transvaginal probe is cleaned according to departmental protocol using Tristel Duo System. Lot number :</p>